

IBO CASE REPORT TEMPLATE
[HERE ENTER PATIENT INITIALS]

INDIAN BOARD OF ORTHODONTICS

CASE REPORT

DATE OF EXAMINATION: *[month, year of examination]*

CANDIDATE NUMBER: *[N]*

CASE CATEGORY : *[N]*

PATIENT'S INITIALS : *[I.I]*

CASE SUMMARY

[A brief description of the case, maximum 100 words]

SECTION 1. PRE-TREATMENT ASSESSMENT

PATIENT DETAILS

Initials:

Sex:

Date of birth:

Age at start of treatment:

PATIENTS COMPLAINTS

RELEVANT MEDICAL HISTORY

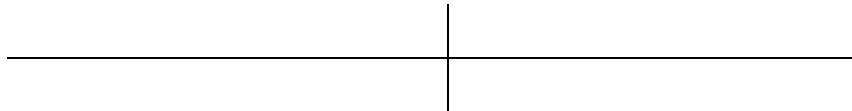
CLINICAL EXAMINATION: EXTRA-ORAL FEATURES

CLINICAL EXAMINATION: INTRA-ORAL FEATURES

Soft tissues:

Oral hygiene:

Erupted teeth present:



General dental condition:

IBO CASE REPORT TEMPLATE
[HERE ENTER PATIENT INITIALS]

CROWDING / SPACING

Maxillary arch:

Mandibular arch:

OCCLUSAL FEATURES

Incisor relationship:

Overjet (mm):

Overbite:

Centrelines:

Left buccal segment relationship:

Right buccal segment relationship:

Crossbites:

Displacements:

Other occlusal features:

IBO CASE REPORT TEMPLATE
[HERE ENTER PATIENT INITIALS]

PRE-TREATMENT PHOTOGRAPHS: EXTRA-ORAL

[Place frontal and profile photographs in the pouch duly mounted]

IBO CASE REPORT TEMPLATE
[HERE ENTER PATIENT INITIALS]

PRE-TREATMENT PHOTOGRAPHS: INTRA-ORAL

[Place anterior, left and right intraoral photographs in the pouch duly mounted]

IBO CASE REPORT TEMPLATE
[HERE ENTER PATIENT INITIALS]

PRE-TREATMENT PHOTOGRAPHS: OTHER RELEVANT VIEWS

[Attach other relevant views to this page-This page is optional]

IBO CASE REPORT TEMPLATE
[HERE ENTER PATIENT INITIALS]

GENERAL RADIOGRAPHIC EXAMINATION

Pre-treatment radiographs taken:

Unerupted teeth:

--	--

Teeth absent:

--	--

Teeth of poor prognosis:

--	--

Other relevant radiographic findings:

IBO CASE REPORT TEMPLATE
[HERE ENTER PATIENT INITIALS]

PRE-TREATMENT RADIOGRAPHS

[Enclose the radiographs in this pouch]

IBO CASE REPORT TEMPLATE
[HERE ENTER PATIENT INITIALS]

OTHER SPECIAL TESTS / ANALYSES

[This is optional. Present details and results of any other tests or measurements which are available and which contribute to the assessment of the case]

IBO CASE REPORT TEMPLATE
[HERE ENTER PATIENT INITIALS]

CEPHALOMETRIC TRACING: PRE-TREATMENT

[Place cephalometric tracing in the pouch]

IBO CASE REPORT TEMPLATE
[HERE ENTER PATIENT INITIALS]

CEPHALOMETRIC ANALYSIS

VARIABLE	PRETREATMENT	NORMAL
Sagittal Skeletal Relationship:		
SNA		
SNB		
ANB		
Wits appraisal		0 mm
Dental Base Relationship:		
Upper incisor to NA (mm/deg)		
Lower Incisor to NB (mm/deg)		
Upper Incisor to SN Plane		
Lower incisor to mandibular plane angle (IMPA)		
Dental Relationship:		
Inter- incisal angle		
Lower incisor to APo line		0-2 mm
Over bite		
Overjet		
Vertical Skeletal Relationships:		
Maxillary - mandibular planes angle		
SN Plane – Mand Plane		
Upper anterior face height		
Lower anterior face height		45: 55%
Face height ratio		
Jarabak Ratio		
Maxillary Length		
Mandibular Length – effective (McNamara)		

IBO CASE REPORT TEMPLATE
[HERE ENTER PATIENT INITIALS]

Soft Tissues:

Lower lip to Ricketts E Plane

-2 mm

Nasolabial Angle

ADDITIONAL CEPHALOMETRIC ANALYSIS (OPTIONAL)

[Where an additional analysis is used, provide clear definitions of the measurements together with means and standard deviations]

INTERPRETATION

IBO CASE REPORT TEMPLATE
[HERE ENTER PATIENT INITIALS]

DIAGNOSTIC SUMMARY

PROBLEM LIST

[Add as few or as many as are appropriate to the case]

- 1.
- 2.
- 3.
- 4.
- 5.
- 6.

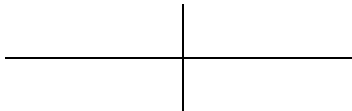AIMS AND OBJECTIVES OF TREATMENT

[Add as few or as many as are appropriate to the case]

- 1.
- 2.
- 3.
- 4.
- 5.

TREATMENT PLAN

Extractions:



Appliances:

Special anchorage requirements:

IBO CASE REPORT TEMPLATE
[HERE ENTER PATIENT INITIALS]

Minor adjunctive surgery:

Major adjunctive surgery:

Additional dental treatment:

Proposed retention strategy:

Additional notes on treatment plan:

Prognosis for stability:

IBO CASE REPORT TEMPLATE
[HERE ENTER PATIENT INITIALS]

SECTION 2. TREATMENT

TREATMENT PROGRESS

Start of active treatment: [Date]

Age at start of active treatment: [years, months]

End of active treatment: [Date]

Active treatment time: [months]

End of retention: [Date]

KEY STAGES IN TREATMENT PROGRESS

[Provide a brief summary of approximately 8 - 10 key stages in the treatment sequence]

DATE	STAGE
1.	
2.	
3.	
4.	
5.	
6.	
7.	
8.	

IBO CASE REPORT TEMPLATE
[HERE ENTER PATIENT INITIALS]

KEY STAGES IN TREATMENT PROGRESS (CONTINUED)

IBO CASE REPORT TEMPLATE
[HERE ENTER PATIENT INITIALS]

MID-TREATMENT PHOTOGRAPHS:

[Optional. Attach any relevant photographs which illustrate treatment mechanics to this page]

IBO CASE REPORT TEMPLATE
[HERE ENTER PATIENT INITIALS]

MID-TREATMENT PHOTOGRAPHS:

[Optional. Attach any relevant photographs which illustrate treatment mechanics to this page]

SECTION 3. POST-TREATMENT ASSESSMENT

OCCLUSAL FEATURES

Incisor relationship:

Overjet (mm):

Overbite:

Centrelines:

Left buccal segment relationship:

Right buccal segment
relationship:

Crossbites:

Displacements:

Functional occlusal features

Other occlusal features:

COMPLICATIONS ENCOUNTERED DURING TREATMENT

IBO CASE REPORT TEMPLATE
[HERE ENTER PATIENT INITIALS]

OCCLUSAL INDICES

[This section is optional]

INDEX	PARAMETER	VALUE
Index of Treatment Need		
Dental Health Component	Start	
	Finish	
Aesthetic Component	Start	
	Finish	
Peer Assessment Rating (PAR)	Start	
	Finish	
	Change	
	% Change	

RADIOGRAPHS TAKEN TOWARDS / AT END OF TREATMENT

Radiographs taken:

Relevant findings:

IBO CASE REPORT TEMPLATE
[HERE ENTER PATIENT INITIALS]

POST-TREATMENT RADIOGRAPHS

[Enclose the radiographs in this pouch]

IBO CASE REPORT TEMPLATE
[HERE ENTER PATIENT INITIALS]

CEPHALOMETRIC TRACING: POST-TREATMENT (Where appropriate)

[Attach cephalometric tracing]

I B O C A S E R E P O R T T E M P L A T E
[H E R E E N T E R P A T I E N T I N I T I A L S]

POST TREATMENT CEPHALOMETRIC ASSESSMENT

VARIABLE	PRETREATMENT	POST-TRT
-----------------	---------------------	-----------------

Sagittal Skeletal Relationship:

SNA

SNB

ANB

Wits appraisal

Dental Base Relationship:

Upper incisor to NA (mm/deg)

Lower Incisor to NB (mm/deg)

Upper Incisor to SN Plane

Lower incisor to mandibular plane angle (IMPA)

Dental Relationship:

Inter- incisal angle

Lower incisor to APo line

Over bite

Overjet

Vertical Skeletal Relationships:

Maxillary - mandibular planes angle

SN Plane – Mand Plane

Upper anterior face height

Lower anterior face height

Face height ratio

Jarabak Ratio

Maxillary Length

Mandibular Length – effective (McNamara)

IBO CASE REPORT TEMPLATE
[HERE ENTER PATIENT INITIALS]

Soft Tissues:

Lower lip to Ricketts E Plane

Nasolabial Angle

ADDITIONAL ANALYSIS (OPTIONAL)

INTERPRETATION

IBO CASE REPORT TEMPLATE
[HERE ENTER PATIENT INITIALS]

CEPHALOMETRIC SUPERIMPOSITION (where appropriate)

Overall superimposition, registered on Sella-Nasion line at Nasion

IBO CASE REPORT TEMPLATE
[HERE ENTER PATIENT INITIALS]

CEPHALOMETRIC SUPERIMPOSITION (where appropriate)

Maxillary and mandibular superimpositions. [Please state registration landmarks]

IBO CASE REPORT TEMPLATE
[HERE ENTER PATIENT INITIALS]

POST-TREATMENT PHOTOGRAPHS: EXTRA-ORAL

[Attach frontal and profile photographs to this page]

IBO CASE REPORT TEMPLATE
[HERE ENTER PATIENT INITIALS]

POST-TREATMENT PHOTOGRAPHS: INTRA-ORAL

[Attach anterior, left and right intraoral photographs to this page]

IBO CASE REPORT TEMPLATE
[HERE ENTER PATIENT INITIALS]

POST-TREATMENT PHOTOGRAPHS: INTRAORAL-OCCLUSAL & OTHER RELEVANT VIEWS

[Attach any other relevant photographs to this page]

SECTION 4. CRITICAL APPRAISAL

[Not more than one page]